

A developmental study of the structural integrity of white matter in autism

Timothy A. Keller, Rajesh K. Kana and Marcel Adam Just

Center for Cognitive Brain Imaging, Department of Psychology, Carnegie Mellon University, Pittsburgh, Pennsylvania, USA

Correspondence and requests for reprints to Timothy A. Keller, Senior Research Associate, Department of Psychology, Center for Cognitive Brain Imaging, Carnegie Mellon University, 5000 Forbes Avenue, Pittsburgh, PA 15213, USA
Tel: +1 412 268 2402; fax: +1 412 268 2804; e-mail: tk37@andrew.cmu.edu

Sponsorship: This research was supported by the Collaborative Program of Excellence in Autism (CPEA) Grant HD35469 from the National Institute of Child Health and Human Development.

Received 21 July 2006; accepted 28 July 2006

Diffusion tensor imaging was used to examine developmental changes in the organization of white matter in a large sample of male participants with autism and controls between the ages of 10 and 35 years. Participants with autism had lower fractional anisotropy in areas within and near the corpus callosum and in the right retrolenticular portion of the internal capsule. Only one area, in the posterior limb of the right internal capsule, showed an

interaction between age and group. The findings suggest that reductions in the structural integrity of white matter in autism persist into adulthood. These reductions may underlie the behavioral pattern observed in autism, as well as findings of reduced functional connectivity in functional magnetic resonance imaging signal between activating cortical areas. *NeuroReport* 18:23–27 © 2007 Lippincott Williams & Wilkins.

Keywords: autism, connectivity, development, diffusion tensor imaging, fractional anisotropy, white matter

Introduction

Increasing evidence from structural imaging studies exists for an atypical developmental trajectory of white matter in autism. Studies of the volume of white matter have suggested an early overgrowth of white matter among young children with autism, followed by reduced white matter in adolescence and adulthood relative to controls [1–4]. Diffusion tensor imaging (DTI) provides the opportunity to go beyond measurement of the volume of white matter to examine its structural integrity on a voxel-by-voxel basis. Fractional anisotropy (FA), a measure derived from diffusion tensor data, is sensitive to developmental changes and pathological differences in axonal density, size, myelination, and the coherence of organization of fibers within a voxel, and thus provides an index of the structural integrity of white matter [5–7].

One study has reported widespread reductions in FA in the white matter of children with autism relative to typically developing controls [8]. Areas of reduced FA found in that study included the corpus callosum, bilateral ventromedial frontal regions, left temporal and occipital regions, and right temporal, occipital, and frontal regions. The mean age of participants in that study was approximately 14 years, and studies of developmental changes in FA among typically developing individuals have demonstrated positive correlations with age through adolescence in many of the areas showing group differences in that study [9–12]. It is possible that the reduction in FA values seen in children with autism represents a lag in the development of the structural

integrity of white matter, that is, such children eventually reach normal levels of FA at a later age than controls. In the present study, we extend the examination of differences in FA between autism and normal development to a sample between ages 10 and 35 years. We employ a voxel-wise multiple regression approach to identify regions showing main effects of participant group and age and their interaction in order to better elucidate the developmental trajectory of FA increases in both typically developing individuals and those with autism.

Methods

Participants

Data from 34 participants with autism and 31 control participants entered the present analysis. All participants were between ages 10 and 35 years, male, right-handed, and Caucasian. Participants in the autism group met the accepted criteria for high functioning autism. (Additional details of the selection and exclusionary criteria for each group can be found elsewhere [13].) No difference was found between groups in mean age (autism, 18.9 ± 7.3 years; control, 18.9 ± 6.2 years), but a reliable difference was found in mean Wechsler full-scale intelligence quotient (IQ) scores (autism, 102.0 ± 14.8 ; control, 109.5 ± 9.0 ; $t(63) = 2.44$, $P < 0.05$). Consequently, examinations of the effects of age and group on the diffusion tensor data were made within the context of multiple regression analysis, with Wechsler full-scale IQ included as an additional covariate.

Each participant signed an informed consent approved by the Carnegie Mellon University and the University of Pittsburgh Institutional Review Boards.

Data acquisition and analysis

Diffusion data were acquired on a 3T Siemens Allegra Scanner (Siemens, Erlangen, Germany) at the Brain Imaging Research Center jointly operated by Carnegie Mellon University and the University of Pittsburgh. A diffusion-weighted, single-shot, spin-echo, echo-planar imaging sequence was used with TR = 4400 ms, TE = 74 ms, bandwidth = 2298 Hz/voxel, FOV = 200 mm, and matrix size = 128 × 128. Thirty-six 3-mm thick slices were imaged (no slice gap) with no diffusion-weighting ($b = 0$ s/mm²) and with diffusion-weighting ($b = 850$ s/mm²) gradients applied in six orthogonal directions. Twelve images of each slice by gradient direction combination were acquired and averaged to produce the final diffusion imaging data set for each participant.

Diffusion tensors and parameter maps were calculated for each participant in native space using standard algorithms [14]. For the present analysis, the diffusion tensor data were reduced to FA maps for each participant. For normalization of the DTI data to a standard space, a custom template was created from the T2-weighted b_0 scans of all participants. SPM2 (Wellcome Department of Cognitive Neurology, London, UK) was used to first normalize each participant's b_0 volume to the Montreal Neurological Institute (MNI) echo-planar imaging template using an affine transformation and 12 iterations of the default SPM2 nonlinear normalization algorithm. These normalized T2-weighted images were then averaged across all participants to produce a new template customized for the present scanner, imaging sequence, and sample of participants. Each participant's original, native-space b_0 volume was then normalized to this new template using the same algorithm, and the transformation parameters for this normalization were applied to the participant's FA map.

Group analyses were carried out using random-effects voxel-wise multiple regression analyses in SPM2. These analyses were conducted on the normalized FA maps after smoothing them with an 8-mm Gaussian filter to accommodate imprecision of the normalization procedure and masking the data at an FA threshold of 0.2 in order to restrict analysis to differences in white matter. All analyses were thresholded at $P < 0.0005$ (two-tailed tests) uncorrected for multiple comparisons, with an extent threshold of 10 voxels to eliminate isolated small areas of FA differences from further consideration. In addition, because our primary interest is in the effect of group on FA, we restricted our

reporting to areas showing main effects of group and interactions between age and group. A step-up hierarchical multiple regression strategy was employed in which we first examined main effects of group on FA, with age and full-scale IQ entered as additional covariates, and then tested for areas showing linear interactions between group and age in predicting FA by including the product of group and age in the same model, and for curvilinear interactions between group and age, by including the product of group and a quadratic term for age in the model. Locations of significant effects of the independent variables were labeled with reference to a DTI-based atlas of white matter tracts [15].

Results

Five regions of white matter showed reliably lower FA values for the group with autism relative to controls when controlling for age and full-scale IQ. These areas are listed in Table 1, and their locations are shown in Fig. 1. Importantly, there were no areas that showed greater FA values for the group with autism relative to controls. Four of the regions were within or near the corpus callosum: one in the posterior midbody and isthmus (Fig. 1a), two in the left and right anterior corona radiata near the genu (Fig. 1bc), and one in the right forceps minor, and likely including fibers passing through the genu (Fig. 1d). An additional area of reduced white matter integrity among the autism group was found in the retrolenticular portion of the right external capsule (Fig. 1e).

Large positive main effects of age on FA, after controlling for group and full-scale IQ, were found distributed throughout frontal, temporal, parietal, and occipital regions of white matter, consistent with previous studies of normal development [9–12]. No regions were found showing linear decreases with age. Among the regions showing a linear increase in FA with age, only an area in the right forceps minor (a cluster of 1580 voxels with a peak t -value of 7.67 at MNI coordinate 16, 54, 0) showed overlap with an area showing a main effect of group. Examination of the effects of age within regions showing an effect of group, however, suggested that most areas showing reduced FA among the group with autism also showed increasing linear trends with age, as can be seen in Fig. 2, which plots FA as a function of age and group for each of the peak voxels of clusters showing a group difference. The exception to this pattern was the cluster in the posterior midbody and isthmus of the corpus callosum, which suggested a group by age interaction, with controls showing no effect of age and individuals with autism showing a trend toward a linear increase (see Fig. 2a).

Table 1 Areas showing reduced FA values for the group with autism relative to the control group after controlling for age and Wechsler full-scale IQ scores

Region	Cluster size	Peak t -value	MNI coordinates		
			x	y	z
a Posterior midbody/isthmus of corpus callosum	25	4.17	-2	-8	28
b Left anterior corona radiata near genu of corpus callosum	30	4.52	-12	36	12
c Right anterior corona radiata near genu of corpus callosum	18	4.63	10	36	12
d Right anterior corona radiata/forceps minor	12	4.32	28	44	6
e Right retrolenticular portion of internal capsule	25	4.01	42	-40	4

Alphabetic labels correspond to region labels in Fig. 1.
FA, fractional anisotropy; IQ, intelligence quotient.

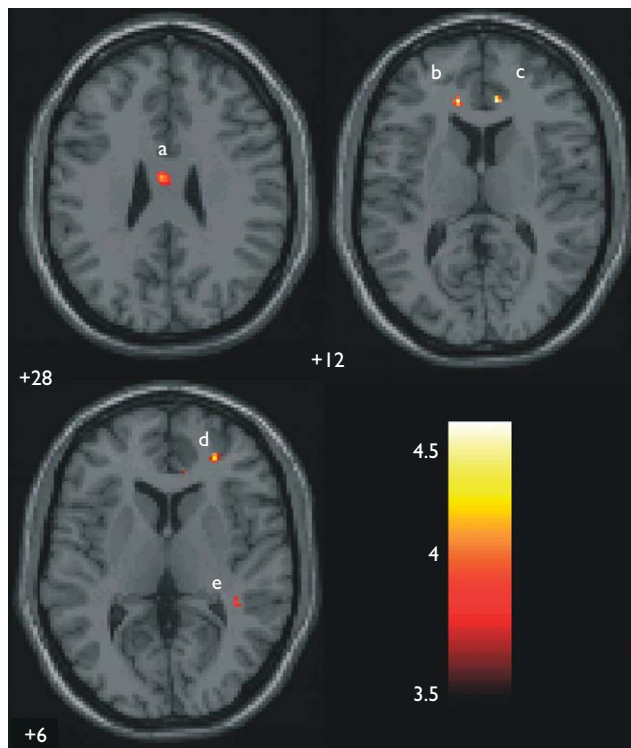


Fig. 1 Areas showing reduced fractional anisotropy values for the group with autism relative to controls after controlling for age and intelligence quotient scores. Labels correspond to those in Table I. The color bar displays *t*-value scale. The left hemisphere is on the left of the image.

The voxel-wise test of the interaction between group and the linear effect of age on FA resulted in a single area in the posterior limb of the right internal capsule showing a reliable effect of age that was conditional upon group membership. This cluster of 129 voxels (peak *t*-value at MNI coordinates 20, -6, -2 = 4.90) survives correction for multiple comparisons at $P < 0.05$ when cluster size and height are jointly considered. Participants with autism showed increasing development of FA throughout the age range examined ($r = 0.53$), whereas controls showed a decrease in FA with development ($r = -0.47$), as shown in Fig. 2f. When a quadratic term for age was included in the model, this same region again showed reliable group \times age interaction (a cluster of 65 voxels with peak *t*-value at MNI coordinates 20, -6, -2 = 4.50), but this model did not result in a significant increase in R^2 over the model including only the linear effect of age.

Discussion

The central finding of the present study was that across a range of ages, the group with autism showed lower FA (controlling for age and IQ) in several areas that may play a crucial role in the neuropathology of autism. No areas were found where participants with autism had higher FA values than controls. Areas showing reduced FA in autism included the posterior midbody and isthmus of the corpus callosum, which likely contain interhemispheric connections between both frontal and parietal cortical regions [16], and fibers in the left and right frontal lobes passing through the genu of the corpus callosum and involving interhemispheric frontal connections. An additional area of reduced FA

among the participants with autism was found in the right posterior limb of the internal capsule. This area contains a number of white matter tracts, including the posterior thalamic radiation, the superior longitudinal fasciculus, the inferior longitudinal fasciculus, and the inferior fronto-occipital fasciculus. Reduced structural integrity in this region among individuals with autism could therefore conceivably affect long-range communication in the right hemisphere among a large number of cortical regions including frontal, parietal, temporal, and occipital areas. Future studies employing diffusion tensor tractography in individual participants may better characterize the particular tracts affected in this region.

No strong evidence for normalization of FA with increasing age in autism was found in the present study. Although there was a trend in this direction in the posterior midbody and isthmus of the corpus callosum, the difference between the slopes of the regression of age on FA for the two groups was not significant. The only region showing a reliable group \times age interaction, the right posterior limb of the external capsule, did not show a pattern of normalization with age. Rather, in this area participants with autism showed an increase in FA with age, whereas controls showed a decrease. Longitudinal studies tracking the developmental trajectory of FA values in this region at younger ages in the two populations will be helpful in assessing whether the pattern found in the present study represents a real developmental difference between the groups. Such studies will also be necessary to relate the findings of developmental abnormalities in the volume of white matter at younger ages [1–4] to abnormalities in its structural integrity.

Lower FA values may reflect decreased fiber density, reduced myelination of fiber tracts, or less directionally coherent organization of fibers within a voxel [5–7], all of which could reflect decreased anatomical connectivity in autism. The examination of other measures derived from DTI data, such as mean diffusivity or intervoxel coherence, may provide additional information about the underlying cause of the reduced anatomical connectivity. In addition, assessment of the relationship between DTI measures and quantitative behavioral measures of autistic symptoms may reveal important relationships between connectivity reductions in particular regions and specific clinical profiles.

The present findings are highly relevant to autism because abnormality in the size of the corpus callosum is a consistent finding in autism [17], and these corpus callosum abnormalities have recently been related to the widespread functional underconnectivity in adults with autism [18,19]. Evidence from functional magnetic resonance imaging studies suggests reduced synchronization in the activation of brain regions in adults with autism in several tasks, including the attribution of social meaning [20], language processing [13], working memory [21], executive functioning [18], and visual imagery [19], leading to speculation that the disorder involves cortical underconnectivity [13,22]. A reduction in the structural integrity of white matter in autism may underlie such differences in functional connectivity and may be responsible for some of the social and cognitive symptoms seen in autism, including deficits in 'theory of mind' [23], weak 'central coherence' [24], and impaired complex information processing [25].

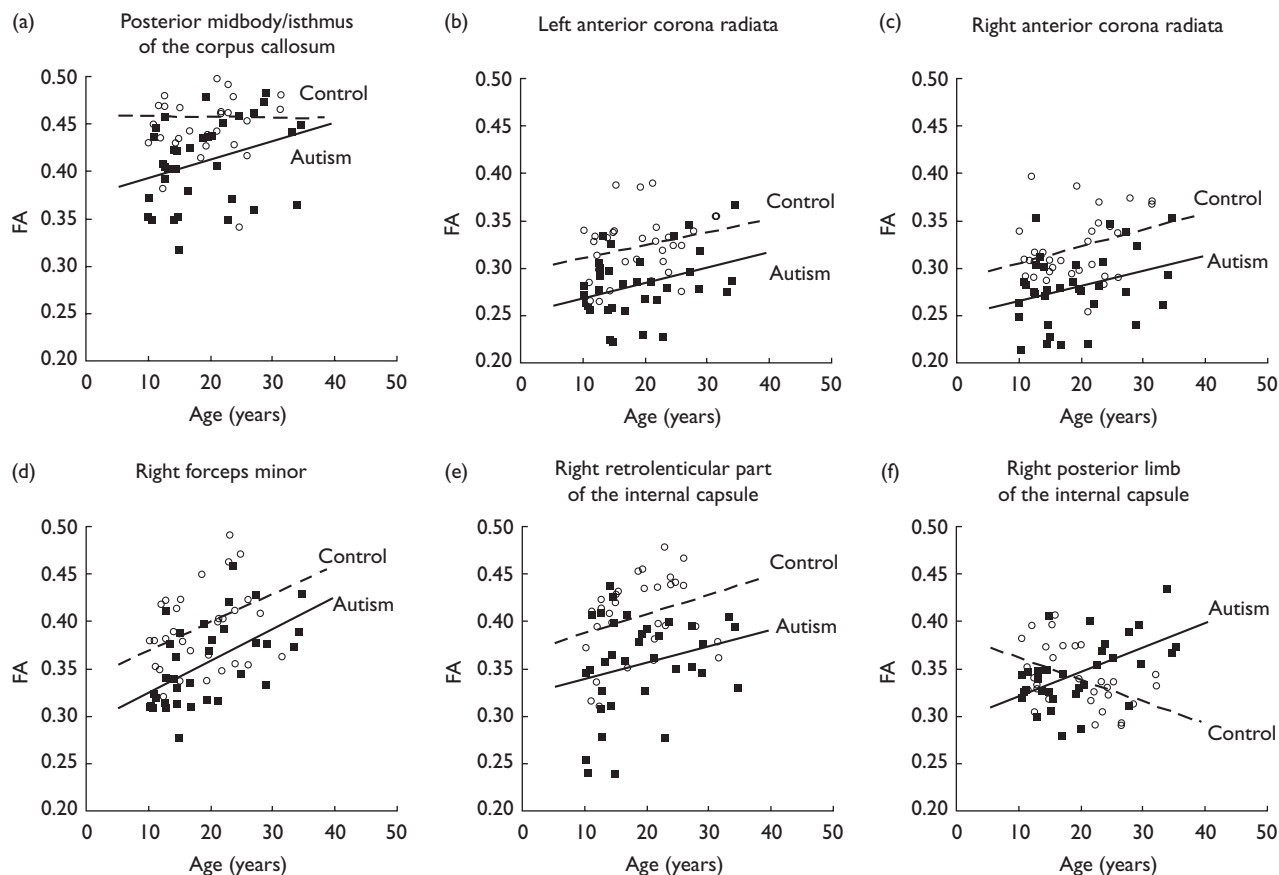


Fig. 2 Plots of the effect of age on fractional anisotropy for each group in regions showing the main effect of group (a–e) and in a region showing an interaction between group and age (f). Open circles, typically developing individuals; closed squares, individuals with autism. FA, fractional anisotropy.

Conclusion

Reductions in the structural integrity of white matter in autism persist in adulthood in regions supporting long-range anatomical and functional connectivity among cortical areas. These abnormalities may contribute to underlying pervasive core processing deficits that have been suggested to be at the root of the behavioral features of the disorder. Future studies examining younger children with autism, additional measures derived from diffusion tensor data, and, most importantly, the relationships among diffusion tensor measures, behavioral measures, and other structural and functional imaging measures, may provide important additional insight into the nature of the white matter abnormality and the nature of autism.

Acknowledgements

The authors wish to thank Kwan-Jin Jung and Brent Frye for pulse sequence advice and software development, and Stacey Becker, Sarah Berson, Sarah Schipul, and Diane Williams for assistance in scanning. The authors also wish to thank the participants and their families for their time and commitment to this research.

References

- Courchesne E, Karns CM, Davis HR, Ziccardi R, Carper RA, Tigue ZD, et al. Unusual brain growth patterns in early life in patients with autistic disorder: an MRI study. *Neurology* 2001; **57**:245–254.
- Herbert MR, Ziegler DA, Makris N, Filipek PA, Kemper TL, Normandin JJ, et al. Localization of white matter volume increase in autism and developmental language disorder. *Ann Neurol* 2004; **55**:530–40.
- Courchesne E, Redcay E, Kennedy DP. The autistic brain: birth through adulthood. *Curr Opin Neurol* 2004; **17**:489–496.
- Waiter GD, Williams JH, Murray AD, Gilchrist A, Perrett DI, Whiten A. Structural white matter deficits in high-functioning individuals with autistic spectrum disorder: a voxel-based investigation. *Neuroimage* 2005; **24**:455–461.
- Basser PJ. Inferring microstructural features and the physiological state of tissues from diffusion-weighted images. *NMR Biomed* 1995; **8**: 333–344.
- Pierpaoli C, Basser PJ. Toward a quantitative assessment of diffusion anisotropy. *Magn Reson Med* 1996; **36**:893–906.
- Beaulieu C. The basis of anisotropic water diffusion in the nervous system: a technical review. *NMR Biomed* 2002; **15**:435–455.
- Barnea-Goraly N, Kwon H, Menon V, Eliez S, Lotspeich L, Reiss AL. White matter structure in autism: preliminary evidence from diffusion tensor imaging. *Biol Psychiatry* 2004; **55**:323–326.
- Klingberg T, Vaidya JC, Gabrieli JDE, Moseley ME, Hedehus M. Myelination and organization of the frontal white matter in children: a diffusion tensor MRI study. *Neuroreport* 1999; **10**:2817–2821.
- Schmithorst VJ, Wilke M, Dardzinski BJ, Holland SK. Correlation of white matter diffusivity and anisotropy with age during childhood and adolescence: a cross-sectional diffusion-tensor MR imaging study. *Radiology* 2002; **222**:212–218.
- Snook L, Paulson L, Roy D, Phillips L, Beaulieu C. Diffusion tensor imaging of neurodevelopment in children and young adults. *Neuroimage* 2005; **26**:1164–1173.
- Barnea-Goraly N, Menon V, Eckert M, Tamm L, Bammner R, Karchemskiy A, et al. White matter development during childhood and adolescence: a cross-sectional diffusion tensor imaging study. *Cereb Cortex* 2005; **15**:1848–1854.

13. Just MA, Cherkassky VL, Keller TA, Minshew NJ. Cortical activation and synchronization during sentence comprehension in high-functioning autism: evidence of underconnectivity. *Brain* 2004; **127**:1811–1821.
14. Bassler PJ, Pierpaoli C. Microstructural and physiological features of tissues elucidated by quantitative-diffusion-tensor MRI. *J Magn Reson B* 1996; **111**:209–219.
15. Mori S, Wakana S, Nagae-Poetscher LM, Van Zijl PCM. *MRI atlas of human white matter*. Amsterdam: Elsevier; 2005.
16. Huang H, Zhang J, Jiang H, Wakan S, Poetscher L, Miller M, et al. DTI tractography based parcellation of white matter: application to the mid-sagittal morphology of corpus callosum. *Neuroimage* 2005; **26**:195–205.
17. Brambilla P, Hardan A, di Nemi SU, Perez J, Soares JC, Barale F. Brain anatomy and development in autism: review of structural MRI studies. *Brain Res Bull* 2003; **61**:557–569.
18. Just MA, Cherkassky VL, Keller TA, Kana RK, Minshew NJ. Functional and anatomical cortical underconnectivity in autism: evidence from an fMRI study of an executive function task and corpus callosum morphometry. *Cereb Cortex* (in press).
19. Kana RK, Keller TA, Cherkassky VL, Minshew NJ, Just MA. Sentence comprehension in autism: thinking in pictures with decreased functional connectivity. *Brain* 2006; **129**:2484–2493.
20. Castelli F, Frith C, Happé F, Frith U. Autism, Asperger syndrome and brain mechanisms for the attribution of mental states to animated shapes. *Brain* 2002; **125**:1839–1849.
21. Koshino H, Carpenter PA, Minshew NJ, Cherkassky VL, Keller TA, Just MA. Functional connectivity in an fMRI working memory task in high-functioning autism. *Neuroimage* 2005; **24**:810–821.
22. Belmonte MK, Allen G, Beckel-Mitchener A, Boulanger LM, Carper RA, Webb SJ. Autism and abnormal development of brain connectivity. *J Neurosci* 2004; **20**:9228–9231.
23. Baron-Cohen S, Leslie AM, Frith U. Does the autistic child have a 'theory of mind'? *Cognition* 1985; **21**:37–46.
24. Frith U. *Autism: explaining the enigma*. Oxford: Blackwell; 1989.
25. Minshew NJ, Goldstein G, Siegel D. Neuropsychologic functioning in autism: profile of a complex informational processing disorder. *J Int Neuropsychol Soc* 1997; **3**:303–316.